

Liposarcomas of the hypopharynx: a systematic review of the literature

Andrea Corvino¹, Giuseppe Riva¹, Matteo Sensini¹,
Massimiliano Garzaro¹, Giancarlo Pecorari¹

Affiliations:

¹ ENT Division, Surgical Sciences Department, University of Turin, Via Genova,3,10126 Turin, Italy

Corresponding author:

Dr. Giuseppe Riva- 1st ENT Division, Surgical Sciences Department, University of Turin, Via Genova,3,10126 Turin, Italy- phone number: +39.011.633.66.88
fax +39.011.633.66.50. mail:giuseppe.riva84@gmail.com

Abstract

Introduction: Liposarcomas are considered the most common type of soft tissue sarcoma in adults. They represent approximately 20% of all mesenchymal malignancies and most frequently involve the retroperitoneum, trunk and extremities. Hypopharyngeal localisation of a liposarcoma is extremely rare. To determine the prevalence of liposarcomas of the hypopharynx, we conducted a systematic review of the literature.

Methods: We performed a systematic search of the literature until 2015 using PubMed and Ovid. The search identified 28 cases of hypopharyngeal liposarcomas. The inclusion criteria were: clinical trials, cohort studies, case-control studies, case reports and case series on hypopharyngeal liposarcomas. From an initial 77 articles, 23 articles were selected for this systematic review. The natural history, imaging features, histology, treatment and prognosis were analysed.

Results: The incidence peaked in the sixth and seventh decades. Diagnostic procedures were based on the barium swallow test, endoscopic examinations, and computed tomography (CT)/magnetic resonance (MR) imaging. A well-differentiated liposarcoma represented the most frequent histological subtype. Surgical excision was the main treatment. Endoscopic resection appeared to be useful for peduncolated tumours of the hypopharynx. The 1-year disease-free survival rate was 89.47%.

Conclusions: A hypopharyngeal liposarcoma is a rare pathology, but it should be kept in mind when a mass of the hypopharynx is discovered. A cervical approach is better, irrespective of the size of the tumour, except for cases in which an endoscopic approach is feasible. Local recurrence is common. Therefore, patients should undergo regular examinations, at least for up to 5 years.

KEY WORDS: liposarcoma; hypopharyngeal neoplasms; hypopharynx; piriform sinus, lateral pharyngotomy; systematic review

Riassunto

Introduzione: I liposarcomi sono considerati il più comune tipo di sarcoma dei tessuti molli negli adulti. Rappresentano circa il 20% di tutte le neoplasie mesenchimali e interessano più frequentemente il retroperitoneo, il tronco e le estremità. La localizzazione ipofaringea è estremamente rara. Lo scopo di questa revisione sistematica è di determinare la prevalenza dei liposarcomi dell'ipofaringe.

Metodi: È stata condotta una ricerca sistematica della letteratura fino al 2015, utilizzando PubMed e Ovid. Sono stati identificati 28 casi di liposarcoma ipofaringeo. I criteri di inclusione sono stati: trial clinici, studi di coorte, studi caso-controllo, report e serie di casi, riguardanti i liposarcomi dell'ipofaringe. Da un totale di 77 articoli ne sono stati selezionati 23 per la revisione. Sono stati analizzati la storia naturale, l'imaging, le caratteristiche istologiche, il trattamento e la prognosi.

Risultati: L'incidenza del liposarcoma raggiunge un picco tra la sesta e la settima decade di vita. Le procedure diagnostiche si basano sul transito con pasto opaco, sulle valutazioni endoscopiche e sull'imaging con tomografia computerizzata o risonanza magnetica. Il sottotipo istologico più frequente è rappresentato dal liposarcoma ben differenziato. L'escissione chirurgica è il trattamento principale. La resezione endoscopica è utile nei casi di liposarcoma peduncolato. La sopravvivenza libera da malattia a 1 anno è 89.47%.

Conclusioni: Il liposarcoma dell'ipofaringe è una patologia rara, ma deve essere tenuta in considerazione nella diagnosi differenziale delle masse ipofaringee. L'approccio cervicale è il migliore, indipendentemente dalle dimensioni del tumore, ad eccezione dei casi in cui è fattibile l'approccio endoscopico. Le recidive locali sono comuni; pertanto, i pazienti devono essere sottoposti a visite regolari di follow-up, per almeno 5 anni.

TAKE-HOME MESSAGE

Hypopharyngeal liposarcomas are extremely rare. This systematic review showed that an adequate diagnostic algorithm is important for correct therapy. Surgical excision represents the main treatment.

Competing interests - none declared.

Copyright © 2016 Andrea Corvino et al. FerrariSinibaldi Publishers

This is an open access article distributed under the Creative Commons Attribution (CC BY 4.0) License, which permits unrestricted use, distribution, and reproduction in any medium, provided the original work is properly cited. See <http://www.creativecommons.org/licenses/by/4.0/>.

Cite this article as - Corvino A, Riva G, Sensini M, Garzaro M, Pecorari G. Liposarcomas of the hypopharynx: a systematic review of the literature. J Health Soc Sci. 2016;1(1):57-66.

DOI 10.19204/2016/lpsr8

Received: 10/12/2015

Accepted: 24/02/2016

Published: 15/03/2016

INTRODUCTION

Liposarcomas are the most common type of soft tissue sarcoma in adults. They represent approximately 20% of all mesenchymal malignancies and most frequently involve the retroperitoneum, trunk and extremities [1]. Hypopharyngeal and oesophageal localisations are extremely rare; the first hypopharyngeal case was reported in 1979 by Frey-Schottman et al. [2], and the first case originating from the cervical oesophagus was reported in 1983 by Mansour et al. [3].

Twenty-eight cases of hypopharyngeal liposarcomas have been reported in the literature (Table 1) [2, 4-25].

The aim of this systematic review was to determine the natural history, imaging features, histology, treatment and prognosis of hypopharyngeal liposarcomas. This is the first systematic review that analyses all reported cases of hypopharyngeal liposarcomas. The evaluation of all cases of such a rare disease is important to improve the diagnosis and therapeutic options in daily clinical practice.

MATERIALS AND METHODS

A systematic review of the literature was performed using PubMed and Ovid, following the statements of Preferred Reporting Items for Systematic Reviews and Meta-Analyses (PRISMA) [26]. No language limitations were set. The primary search was performed using the terms “(liposarcoma OR lipomatous tumor) AND (hypopharynx OR hypopharyngeal)”. The inclusion criteria were clinical trials, cohort studies, case-control studies, case reports and case series on hypopharyngeal liposarcomas published up to and including 2015. The abstracts of all suitable articles were examined. The references of the selected publications were assessed to identify further reports not found by database searching; the same selection criteria were applied. Two independent reviewers (CA, RG), working separately, extracted the data from all the eligible studies, which were subsequently crosschecked. All retrieved full-texts articles were included in the review by a consensus of all the authors. From 77 articles, 23 articles

were selected for inclusion in this systematic review (Fig. 1). All the selected articles were case reports or case series. The survival rate was calculated.

Numerical continuous variables were expressed as means \pm standard deviation and nominal variables were described by the absolute and relative (%) frequency.

NATURAL HISTORY AND DIAGNOSIS

The first symptom of a hypopharyngeal liposarcoma is intermittent, gradually worsening dysphagia, initially to solid food and then to liquids. This can be reported for months before the diagnosis. Dysphagia is usually accompanied by weight loss due to the diagnostic delay, which is caused by the nonspecific nature of the symptoms. The sensation of a foreign body in the throat, hoarseness and airway obstruction are sometimes reported. Rarely, oral extrusion of an elongated smooth mass is observed. The literature contains no report of palpable cervical lymphadenopathies.

Basing on the available data, the mean age is 57.46 ± 17.88 years (range 20–90 years), with a peak in the sixth and seventh decades ($n=14$). The male/female ratio is 25/2. Important factors in the aetiology of liposarcomas include genetics, trauma and prior irradiation exposure. Neurofibromatosis (von Recklinhausen's disease) and familial cancer syndromes, which is inherited as an autosomal dominant trait, are associated with an increased risk of liposarcomatous transformation [27]. There are no reports of a correlation with alcohol and smoking.

The diagnostic procedures for liposarcomas are based mainly on the barium swallow test and endoscopic examinations. In patients with liposarcomas, barium swallow examinations most often show a smooth-walled filling defect and widened atonic oesophagus. Flexible fibre optic laryngoscopy usually reveal a soft tissue mass, apparently arising from the piriform sinus ($n=17$), posterior wall of the hypopharynx ($n=6$) or post-cricoid area ($n=3$), without vocal fold motility disorders. Flexible oesophagogastroduodenoscopy re-

presents an important tool for revealing pedunculated polypoid masses or an apparent ab extrinsec compression in the cervical oesophagus. Transmural liposarcomas present as an apparent ab extrinsec compression and four cases were reported.

Radiological investigations are necessary in most cases to determine the precise size, localisation and extension of the tumour and its association with neurovascular structures. They are also necessary to detect distant metastases [27].

In the past, oesophagography with gastrographin was used to show a dilated oesophagus, with disomogeneous contrast opacification due to multiple filling defects throughout the oesophagus, sometimes from the cricopharyngeus down to the gastroesophageal junction. No coordination disorder of swallowing is usually observed in cases of pedunculated liposarcomas. However, oesophagography with gastrographin is now considered obsolete. Computed tomography (CT) and magnetic resonance (MR) can better define the pathology.

In cases of liposarcomas of the hypopharynx, transmural liposarcomas or liposarcomas protruding into the lumen, CT imaging reveals a heterogeneous mass, with fat-like density. The mass is usually mildly enhanced after the administration of intravenous contrast medium. The contours of the tumor are usually smooth [28].

MR scans reveal an inhomogeneous signal intensity mass with internal high-signal intensity foci on n-phase T1-weighted images of a dilated oesophagus and decreased signal intensity of the foci on out-of-phase T1-weighted images, indicating a fat-containing mass. A heterogeneous mass is also observed on T2-weighted images. After the administration of gadolinium, the mass is inhomogeneously enhanced. The appearance of the liposarcoma depends on its degree of differentiation with a more differentiated tumour having a more intense fat signal [28].

A definitive diagnosis can be achieved by performing a biopsy under a laryngoscope. Macroscopically the tumour presents as a

soft, yellow, well-circumscribed and slowly growing mass, usually covered by normal mucosa. The liposarcoma may be pedunculated or transmural. The tumour size (maximum dimension) ranges from 3 to 21.5 cm (mean 7.60 ± 5.77 cm). In five cases, the maximum dimension was greater than 15 cm. Only two patients had a liposarcoma greater than 20 cm.

The most widely accepted classification system is that of Enzinger and Weis, who divided these tumours into five subtypes: well differentiated, myxoid, pleomorphic, round cell and dedifferentiated [29, 30]. An atypical lipomatous tumour is considered synonymous with a well-differentiated liposarcoma. Dedifferentiation is defined by the coexistence of a non-lipogenic sarcoma of variable histological grade and a well-differentiated liposarcoma. Liposarcomas showing combined features are defined as mixed-type liposarcomas.

A well-differentiated liposarcoma ($n=20$) was the most common type reported. Dedifferentiated ($n=3$) and mixoid liposarcoma ($n=2$) of the hypopharynx were also observed. Only one patient with a mixed-type liposarcoma was reported in the literature. No cases of hypopharyngeal round cell liposarcomas were reported.

TREATMENT AND PROGNOSIS

The main treatment for liposarcomas is surgical excision. Incomplete excision is associated with an increased risk of local recurrence (80% in some studies). Therefore, support is growing for the use of post-operative radiotherapy. However, no study has provided conclusive evidence supporting chemotherapy in the treatment of head and neck liposarcomas [27].

As the fascia surrounding a liposarcoma is not a true enveloping layer, excision should be as wide and meticulous as possible. However, the extent of tumour excision is limited in the head and neck region because of the close proximity to neurovascular structures. Due to the low rate of nodal metastasis, treatment of lymph node areas is not indicated. In well-differentiated liposarcomas, in cases of

complete surgical resection, no adjuvant treatment is recommended. In cases of frequent recurrence, tumour dedifferentiation should be suspected [21].

There are two surgical approaches for hypopharyngeal liposarcomas: the cervical approach (lateral pharyngotomy) and endoscopic surgery. Endoscopic resection can be useful if there is evidence of a tumour peduncle and potential for curative resection [31]. Alternatively, endoscopic resection may provide palliation to patients with unresectable disease or may be followed by surgical resection in those with diseased margins. Simple excision, either endoscopically or via the external pharyngotomy approach, represents the most frequent treatment of cases reported in the literature, with a slight prevalence of the cervical approach. In only one case, partial laryngectomy was necessary. Two patients underwent post-operative radiotherapy or chemotherapy. However, data on chemotherapy schemes and radiotherapy doses are not reported in the original papers.

The advantages of a transoral endoscopic approach with a CO₂ laser are lower morbidity and the ability to resume oral feeding within 1 – 2 days. Moreover, this approach removes the need for tracheostomy, and the hospitalisation-time is shorter [17].

In cases of recurrence, more demolitive surgical approaches, such as total laryngectomy or total oesophagectomy, are needed. Local recurrence was reported in 9 (32%) cases. The average time between the first treatment and recurrence was 42.28 months. Therefore, pa-

tients should undergo regular examinations to rule out local recurrence.

The survival rate of head and neck liposarcomas compares favourably with that reported for liposarcomas at other sites, particularly those in the retroperitoneum, where tumours have a poor prognosis [27]. The most reliable prognostic factors for patients with a hypopharyngeal liposarcoma are the grade, histological subtype, location and adequacy of the surgical treatment [27]. The 1-year disease-free survival rate is 89.47%. However, as some of the reported studies lack follow-up data, these survival rates are not conclusive.

CONCLUSIONS

The hypopharynx represents a rare site of a liposarcoma. Twenty-eight cases of hypopharyngeal liposarcomas are described in the literature. Although a hypopharyngeal liposarcoma represents a rare pathology, it should be kept in mind when a mass of the hypopharynx is discovered. The traditional evaluation is based on the barium swallow test and endoscopy. The fatty nature of the lesion is confirmed by a CT scan and/or MR. The main treatment for liposarcomas is wide surgical excision. The endoscopic approach plays an important role in management. Survival among patients with liposarcomas is dependent on the histological type and location. Local recurrence is common, but the risk of lymph node or distant metastasis is very low. Patients should undergo regular examinations to rule out local recurrence, at least up to 5 years.

Table 1. Hypopharyngeal liposarcoma: review of the literature

Reference	Year of publication	Age (y)	Sex	Type of lesion	Tumor size (cm)	Site	Histology	1° Treatment	Re-currence	TTR	2° treatment	Follow up
Frey-Schottman et al. [2]	1979	52	M	NA	NA	PS	WDL	SE	Yes	3 y	LP, pRT	NED 8 y
Nofal et al. [4]	1989	62	M	NA	6.5	L PS	WDL	EE	No	---	---	NED 14 mo
Wenig et al. [5]	1990	60	M	NA	2	L PS	WDL	SE	Yes	5 y	SE	DND 17 y
Wenig et al. [5]	1990	59	M	NA	5.5	R PS	WDL	SE	Yes	6 mo	SE	NED 25 y
Wenig et al. [5]	1990	46	M	Polyp	NA	L PS	WDL	SE	Yes	1 y	TL, pRT	NED 14 y
Wenig et al. [5]	1990	77	M	Polyp	4	R PS	WDL	SE	Yes	3 y	TL	NED 6 y
Baj et al. [6]	1991	63	M	Polyp	4.6	R PS	WDL	LP	No	---	---	NED 5 y
Wenig et al. [7]	1995	25	M	Polyp	NA	L PS	WDL	LP	No	---	---	NED 12 mo
Wenig et al. [7]	1995	57	M	Polyp	14.5	PS	WDL	EE	Yes	14 y	LP	NED 16 y
Wambeek et al. [8]	1996	60	M	Polyp	NA	PCA, R PS	WDL	SE, pRT, pCT	No	---	---	NED 12 mo
Reed et al. [9]	1996	NA	M	Polyp	21.5	L PS	WDL	LP	No	---	---	NED 69 mo
Fahmy et al. [10]	1998	51	M	Polyp	NA	L PS	WDL	LP	No	---	---	NED 2 mo
Mandell et al. [11]	1999	90	F	Trans-mural	6.5	PCA, R PS	WDL	LP	No	---	---	NED 9 mo
Mouret et al. [12]	1999	56	M	Polyp	10	PWH, L PS	MTL	LP	Yes	2.5 mo	EE	NED 49 mo
Almela Cortés et al. [13]	2002	71	M	Polyp	11	PWH	WDL	LP	Yes	2 y	TE	NA
Sanz Gonzalo et al. [14]	2002	81	M	Polyp	NA	R PS	ML	LP	No	---	---	NED 4 y
Gonzales-Lois et al. [15]	2002	69	M	Polyp	3	PS	DDL	PL	No	---	---	NED 6 mo
Cannizzaro et al. [16]	2003	20	M	NA	NA	NA	PL	SE	No	---	---	NED 8 y
Luna-Ortiz et al. [17]	2009	23	M	Trans-mural	9.5	R PS	ML	LP	Yes	3 y, 7 y and 8 y	3 y NA 7 y EE, 8 y EE	NED 1 y
Giordano et al. [18]	2010	50	M	Polyp	5	R PS	DDL	SE	No	---	---	NED 6 mo
McQueen et al. [19]	2010	50	M	Polyp	4	PWH, R PS	ALT/WDL	EE	NA	---	---	NA
El Ouakif et al. [20]	2011	64	M	Polyp	NA	PWH, L PS	WDL	LP, pRT	No	---	---	NED 1 y
El Ouakif et al. [20]	2011	80	M	Trans-mural	NA	L PS	WDL	EE	No	---	---	NED 6 mo
Takano et al. [21]	2011	56	M	Trans-mural	NA	PWH	WDL	EE	No	---	---	NED 24 mo
Nouri et al. [22]	2011	34	F	Polyp	5	R PS	WDL	EE	No	---	---	NED 12 mo
Bergmark et al. [23]	2012	57	M	Polyp	11	PCA, L PS	WDL	EE	No	---	---	NA
Sotirović et al. [24]	2014	NA	NA	NA	NA	NA	NA	NA	NA	---	---	NA
Riva et al. [25]	2015	81	M	Polyp	21	PCA, L PS	DDL	LP	No	---	---	NED 12 mo

M = male F = female
 R = right L = left PS = piriform sinus PCA = postcricoid area PWH = posterior wall of hypopharynx
 ALT = atypical lipomatous tumor DDL = dedifferentiated liposarcoma ML = myxoid liposarcoma MTL = mixed type liposarcoma PL = pleomorphic liposarcoma WDL = well differentiated liposarcoma
 SE = simple excision (either endoscopically or via external pharyngotomy approach) EE = endoscopic excision LP = lateral pharyngotomy PL = partial laryngectomy TL = total laryngectomy TE = total esophagectomy
 RT = exclusive radiotherapy CT-RT = exclusive chemoradiotherapy pRT = postoperative radiotherapy pCT = postoperative chemotherapy
 TTR = time to recurrence
 NED = alive with no evidence of disease DND = dead with no evidence of disease DWD = dead of other causes with probable disease
 NA = not available

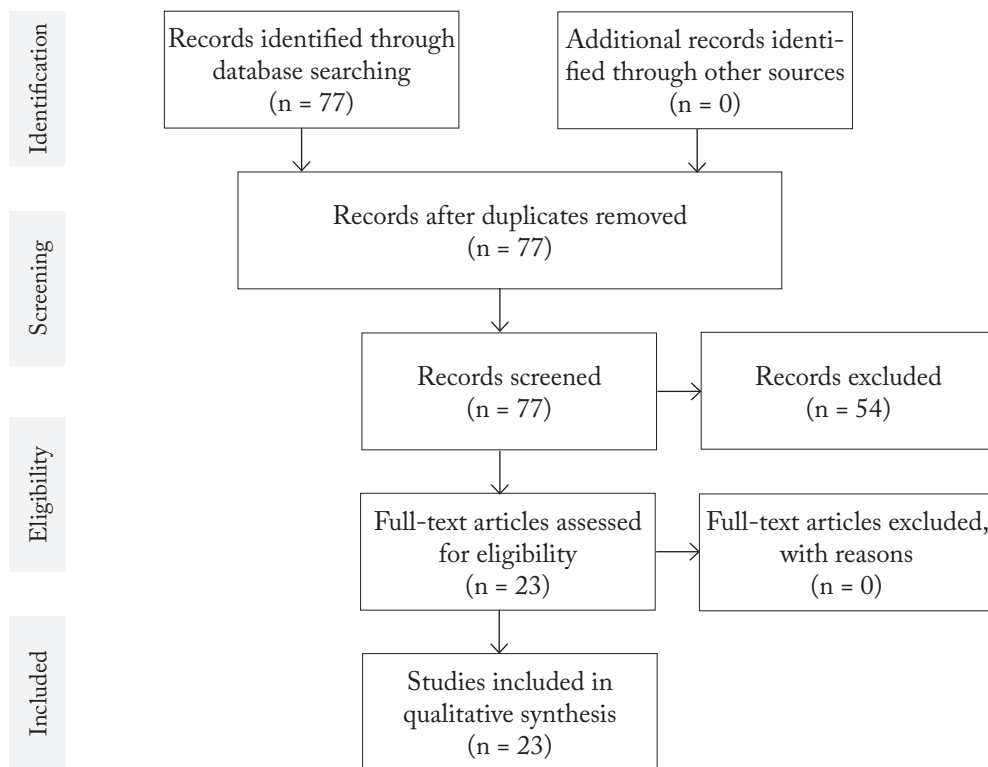


Figure 1. Flow Diagram of Study Selection

References

1. Riva G, Sensini M, Corvino A, Garzaro M, Pecorari G. Liposarcoma of hypopharynx and esophagus: a unique entity? *J Gastrointest Cancer*. 2016 Feb 13 [cited 2016 Feb 20]. doi 10.1007/s12029-016-9808-6. [Epub ahead of print].
2. Frey-Schottman ML, Stiens R. Liposarkom im Hypopharynxbereich. *Arch Ohr Nas Kehlkopf*. 1979;223(2):419-422.
3. Mansour KA, Fritz RC, Jacobs DM, Vellios F. Pedunculated liposarcoma of the esophagus: a first case report. *J Thorac Cardiovasc Surg*. 1983;86(3):447-450.
4. Nofal F, Thomas M. Liposarcoma in the pharynx. *J Laryngol Otol*. 1989;103(11):1080-1082.
5. Wenig BM, Weiss SW, Gnepp DR. Laryngeal and hypopharyngeal liposarcoma. *Am J Surg Pathol*. 1990;14(2):134-141.
6. Baj R, Najwer K, Wierzbicki J, Zieliński KW. Giant liposarcoma of the hypopharynx. *Otolaryngol Pol*. 1991;45(6):463-6.
7. Wenig BM, Heffner DK. Liposarcomas of the larynx and hypopharynx: a clinicopathologic study of eight new cases and a review of the literature. *Laryngoscope*. 1995;105(7 Pt 1):747-756.
8. Wambeek NDK, Mendelson RM. Liposarcoma of the hypopharynx. *Australasian Radiology*. 1996;40(2):165-168.
9. Reed JM, Vick EG. Hypopharyngeal liposarcoma. *Otolaryngol Head Neck Surg*. 1996;114(3):499-500.
10. Fahmy FF, Osborne J, Khalil HS, Rodgers B. Well-differentiated liposarcoma of the hypopharynx. *J Laryngol Otol*. 1998;112(9):880-882.
11. Mandell DL, Brandwein MS, Woo P, Som PM, Biller HF, Urken ML. Upper aerodigestive tract liposarcoma: report on four cases and literature review. *Laryngoscope*. 1999;109(8):1245-1252.
12. Mouret P. Liposarcoma of the hypopharynx. A case report and review of the literature. *Rev Laryngol Otol Rhinol (Bord)*. 1999;120(1):39-42.
13. Almela Cortes R, Moreno Carazo A, Martin Rodriguez L. Laryngeal and hypopharyngeal liposarcoma. Report of a case and literature review. *An Otorrinolaringol Ibero Am*. 2002;29(5):431-438.
14. Sanz Gonzalo JJ, Martínez Molina P, Ribalta Farres MT, Sabater Matadelabarata F. Liposarcoma of the hypopharynx. *Acta Otorrinolaringol Esp*. 2002;53(1):60-63.
15. Gonzalez-Lois C, Ibarrola C, Ballestin C, Martanez-Tello FJ. Dedifferentiated liposarcoma of the pyriform sinus: report of a case and review of the literature. *Int J Surg Pathol*. 2002;10(1):75-79.
16. Cannizzaro MA, Cavallaro A, Veroux M, Costanzo M, Ferrà F, Veroux P. A case of pleomorphic liposarcoma involving a parahypopharyngeal site. *Chir Ital*. 2003;55(3):451-456.
17. Luna-Ortiz K, Campos-Ramos E, Carmona-Luna T, Mohar-Betancourt A, Ferrari-Carballo T. Laser resection of liposarcoma of the hypopharynx. *Med Oral Patol Oral Cir Bucal*. 2009;14(5):E252-256.
18. Giordano G, Corcione L, Gnetti L, Mercante G, Ferri T. Dedifferentiated liposarcoma of the pyriform sinus. *Oral Oncology Extra*. 2006;42(4):176-180.
19. McQueen C, Montgomery E, Dufour B, Olney MS, Illei PB. Giant hypopharyngeal atypical lipomatous tumor. *Adv Anat Pathol*. 2010;17(1):38-41.
20. El Ouakif F, Decourselle F, Schultheis D. Liposarcoma of the hypopharynx: two case reports and literature review. *Rev Laryngol Otol Rhinol (Bord)*. 2011;132(4-5):245-250.
21. Takano K, Kondoh A, Matsumiya H, Himi T. A well-differentiated liposarcoma of the hypopharynx. *Otolaryngol Head Neck Surg*. 2011;144(3):479-480.
22. Nouri H, Hassani R, Aderdour L, Raji A. The well-differentiated liposarcoma of the hypopharynx. *Eur Ann Otorhinolaryngol Head Neck Dis*. 2011;128(3):143-145.
23. Bergmark R, Jung D, Vakharia K, Gray ST, Lin DT, Rosenberg AE. Pathology quiz case 1. Liposarcoma of the hypopharynx. *Arch Otolaryngol Head Neck Surg*. 2012;138(3):313-315.

24. Sotirović J, Vukomanović-Djurdjević B, Baletić N, Pavićević L, Bijelić D, Perić A. Recurrent lipomatous tumor of hypopharynx: case report and literature review. *Acta Clin Croat*. 2014 Sep;53(3):365-8.
25. Riva G, Sensini M, Corvino A, Vittone F, Garzaro M, Pecorari G. Rare giant pedunculated liposarcoma of the hypopharynx: case report and review of literature. *J Gastrointest Cancer*. 2015 Oct 8 [cited 2016 Jan 15]. [Epub ahead of print]. doi 10.1007/s12029-015-9767-3.
26. Moher D, Liberati A, Tetzlaff J, Altman DG, The PRISMA Group (2009). Preferred Reporting Items for Systematic Reviews and Meta-Analyses: The PRISMA Statement. *PLoS Med*. 2009;6(7):e1000097. doi:10.1371/journal.pmed1000097.
27. Gritli S, Khamassi K, Lachkhem A, Touati S, Chorfa A, Ben Makhlof T, et al. Head and neck liposarcomas: a 32 years experience. *Auris Nasus Larynx*. 2010;37(3):347-351.
28. Chung JJ, Kim MJ, Kim JH, Lee JT, Yoo HS, Kim KW. Imaging findings of giant liposarcoma of the oesophagus. *Yonsei Med J*. 2003;44(4):715-718.
29. Fletcher CDM, Sundaram M, Rydholm A, Coindre JM, Singer S. Soft tissue tumours: Epidemiology, clinical features, histopathological typing and grading. In: Fletcher CDM, Krishnan Unni K, Mertens F, editors. *World Health Organization classification of tumours. Pathology and genetics of tumours of soft tissue and bone*. Lyon: IARC Press; 2002. p. 12-18.
30. Enzinger FM, Weis SW. *Soft tissue tumors*. St. Louis: Mosby; 1995. p. 431-66.
31. Will U, Lorenz P, Urban H, Meyer F. Curative endoscopic resection of a huge pedunculated esophageal liposarcoma. *Endoscopy* 2009;39 Suppl 1:E15-16.

